

WILL GRUNDY CME STUDY GUIDE

FEBRUARY 2009

1. An ECG tracing shows the heart's electrical / mechanical activity. It does not provide information regarding force of contraction or blood pressure or electrical / mechanical events.
2. Leads produce different ECG tracings:
 - If depolarization moves toward a negative / positive electrode, ECG shows an upward deflection
 - If the wave moves toward a negative / positive electrode, a negative deflection appears on the ECG
3. Check all of the following that can be obtained from single lead monitoring:
 - Quality or presence of pumping action
 - Regularity (rhythm)
 - Rate (bpm)
 - Presences or location of an infarct
 - Chamber enlargement
 - Length of time it takes to conduct the impulse thru various parts of the heart / conduction system: PR Interval, QRS interval
4. List the EKG Criteria for a Normal Sinus Rhythm
 - Rate:
 - Rhythm:
 - P waves:
 - PR Interval:
 - QRS Complex:
5. An abnormal ST-segment elevation on the ECG is caused by the flow of current between the pathologically depolarized or damaged muscle and the normal repolarized areas or undamaged areas.
TRUE or FALSE

6-10.

Lead	Location of Infarction	Coronary Artery Involved
II, III, aVF		
V1, V2		
V3, V4		
I, aVL, V5, V6		

11. Occlusion of which coronary artery is most likely to be associated with sudden cardiac death?

12. Narrowing or partial occlusion of the right coronary artery is most likely associated with which of the following?

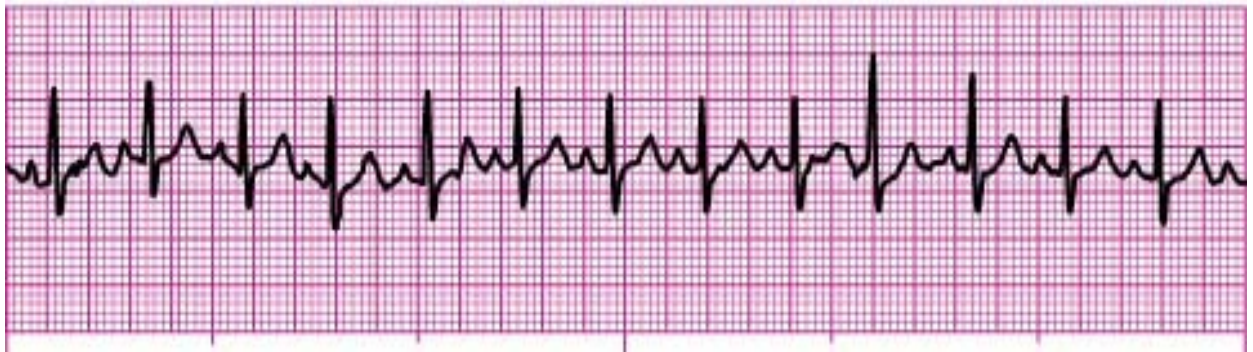- A. anterior wall ischemia
- B. lateral wall ischemia
- C. posterior wall MI
- D. inferior wall MI

13. Per SMO, a 12-lead ECG should be obtained at which point in the treatment sequence of a suspected MI patient?

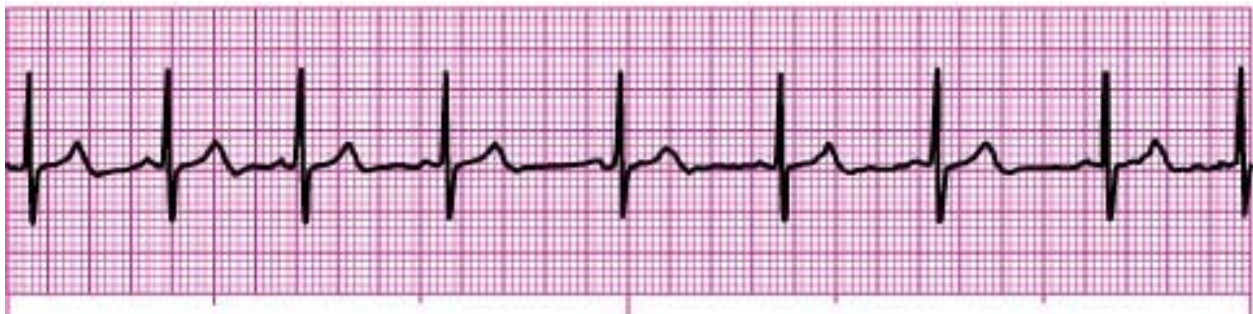- A. following ASA administration, but before NTG
- B. in the ambulance
- C. during IMC
- D. following initial NTG administration

14. Knowing that leads V3, V4 and V5 are on the left anterior chest around the midclavicular line, ST-segment elevation in all three leads would indicate _____ wall ischemia.
- A. lateral
 - B. anterior
 - C. posterior
 - D. inferior
15. Which of the following combinations of leads would give you the most effective view of the inferior wall of the myocardium?
- A. II, III, aVF
 - B. v1, v2, v3
 - C. I, aVL, v6
 - D. v3, v4, v5
16. Lead V1 is located at the:
- A. L sternal border, 4th ICS
 - B. R shoulder
 - C. L midaxillary line at the 5th ICS
 - D. R sternal border, 4th ICS

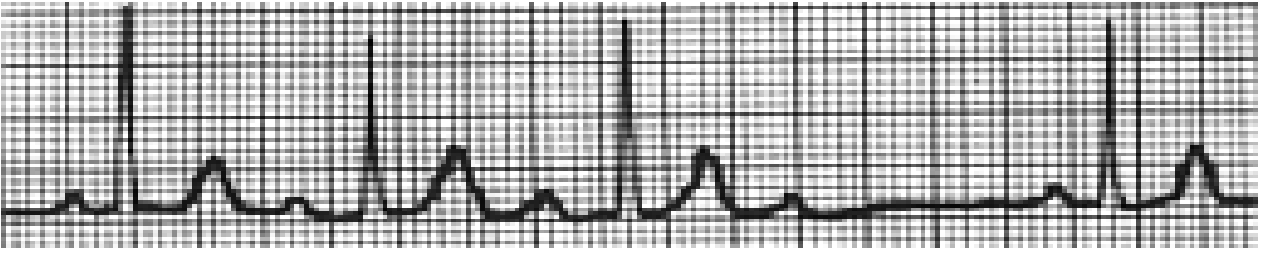
17.



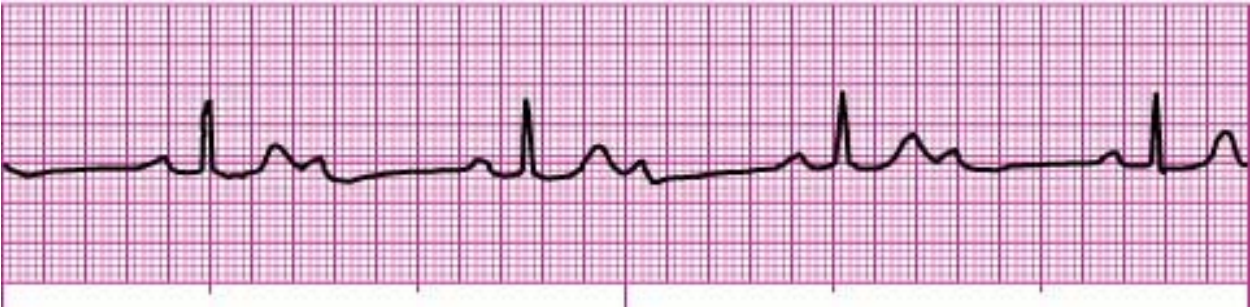18.



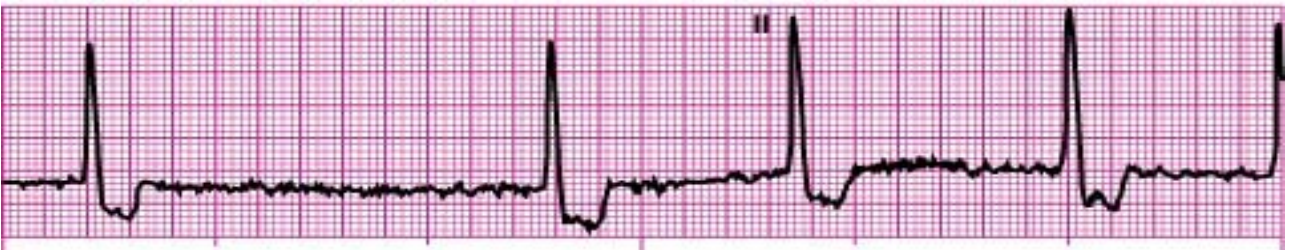19.



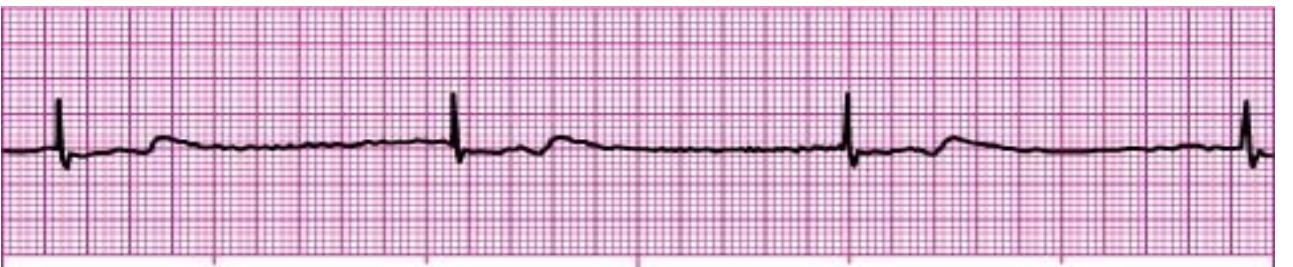20.



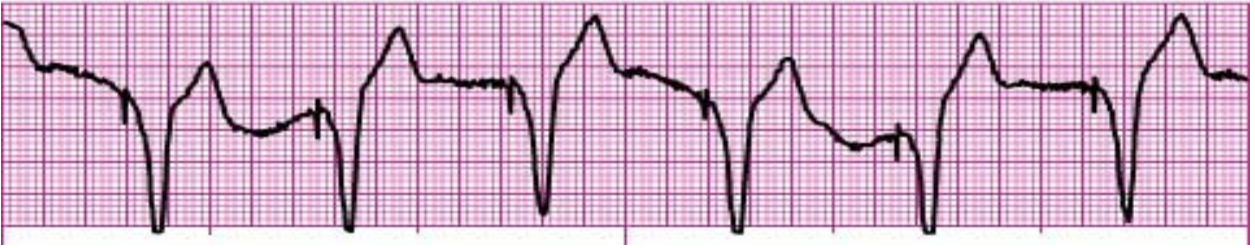21.



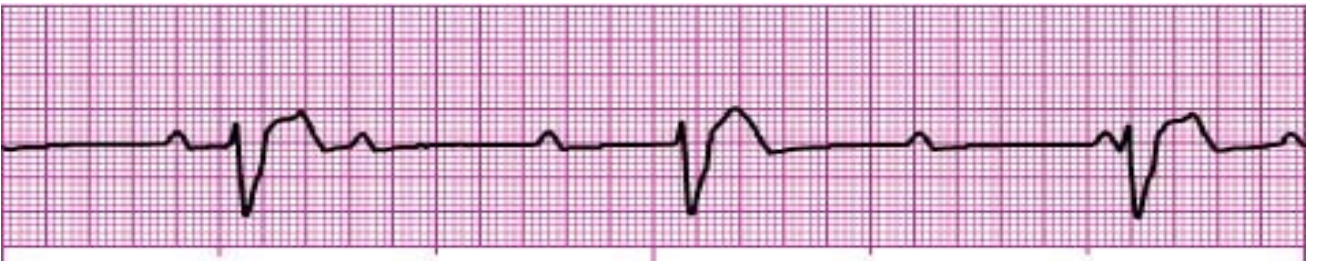22.



23.



24.



25.

